DOI: 10.7860/JCDR/2026/91717.24765

Case Report

Dentistry Section

Non-syndromic Multiple Supernumerary Teeth in the Maxilla and Mandible: A Case Report Highlighting the Diagnostic Role of CBCT

SIVAGAMI MUTHUKRISHNAN[1], PRIYADARSHINI KEDARNATH[2], ASHA JEYAKUMAR[3], JEYA VARSHINI RAVI[4], HEMA NANDHINI[5]

BY-NC-ND

ABSTRACT

Supernumerary teeth are defined as teeth that exceed the normal complement of the dentition and may occur in any region of the dental arch. Their occurrence in multiple numbers, without association with any syndrome, is relatively uncommon. These additional teeth may lead to various complications such as crowding, caries, delayed eruption, and difficulty in maintaining oral hygiene. The authors present a case report of a 32-year-old male patient who presented with pain in the left mandibular posterior region. Clinical examination revealed a partially erupted mandibular third molar and proximal caries in relation to tooth 34. Multiple supernumerary teeth were observed on the lingual aspect of the bilateral mandibular premolar region and on the palatal aspect of the maxillary arch. Cone Beam Computed Tomography (CBCT) was performed to evaluate the exact number, morphology, and position of the supernumerary teeth, revealing five supernumerary teeth in the mandibular arch and two in the maxillary arch. Based on the clinical and radiological findings, the patient underwent endodontic treatment of tooth 34 and extraction of the mandibular supernumerary teeth. This case highlights the importance of thorough clinical examination combined with advanced imaging modalities such as CBCT in the comprehensive evaluation of impacted and supernumerary teeth, thereby ensuring accurate diagnosis and appropriate treatment planning.

Keywords: Bicuspid, Hyperdontia, Impacted supernumerary tooth, Mandibular premolar region

CASE REPORT

A 32-year-old male patient reported to the dental outpatient department with a chief complaint of pain in the left lower posterior region of the jaw for the past one week. The pain was initially mild in intensity, gradually increased over time, and became intense over the last day prior to presentation. The patient had no relevant past dental history. The patient's medical and family history was non-contributory, and no history suggestive of any systemic or genetic disorder was reported.

On intraoral examination, the pain appeared to be associated with a partially erupted mandibular third molar, and proximal caries was suspected in relation to tooth 34. Tooth 34 was tender on percussion. In the maxillary arch, one supernumerary tooth was clinically observed in relation to the palatal aspect of the left premolar region [Table/Fig-1a]; this was not associated with any hygiene-related complications. Two supernumerary teeth were also evident on the lingual aspect of the mandibular premolar region on either side, in relation to teeth 44 and 45 on the right-side and teeth 34 and 35 on the left-side [Table/Fig-1b,c]. These supernumerary teeth contributed to food lodgement, interproximal caries on the distal surface of tooth 34, and compromised oral hygiene in the affected region.As the patient was unable to precisely localise the site of pain, two possible sources were considered: pericoronitis associated with the partially erupted mandibular third molar and pulpal/periapical pain arising from the carious, percussion-tender first premolar (tooth 34).

An Intraoral Periapical radiograph (IOPA) was obtained in relation to tooth 34 [Table/Fig-2a], which revealed deep caries; however, due to superimposition of the adjacent supernumerary teeth, the extent of pulpal involvement could not be clearly determined. The patient was therefore referred for CBCT imaging to enable a comprehensive assessment of the number, morphology, and spatial orientation of



[Table/Fig-1]: Clinical picture showing supernumerary teeth in maxilla and mandible (Black arrow).

the supernumerary teeth and their relationship to adjacent roots and structures. Cone-Beam Computed Tomography (CBCT) scans were acquired using the CS 9600 imaging system (Carestream Dental, Atlanta, GA, USA). The Field Of View (FOV) was restricted to 10 × 10 cm to cover the region of interest, with a voxel resolution of 0.075 mm.A three-dimensional reconstruction confirmed a total of seven supernumerary teeth, five within the mandibular arch and two within the maxillary arch [Table/Fig-2b,c] and also revealed pulpal involvement of tooth 34, which had not been apparent on the IOPA.

CBCT revealed supernumerary teeth on the lingual aspect of the bilateral mandibular premolar-molar regions [Table/Fig-3a]. Two supernumerary teeth were identified on the left-side, positioned between teeth 34-35 and 35-36, respectively. Both were vertically

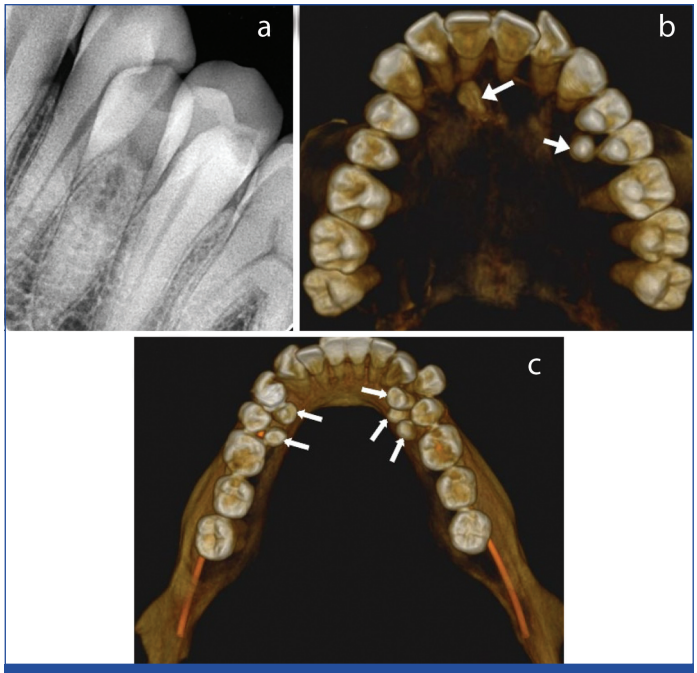

[Table/Fig-2]: Two-dimensional image a) Preop RVG showing proximal caries in 34 with superimposition of supernumerary teeth. Three-dimensional images; b) Maxillary arch showing two supernumerary teeth; c) Mandibular arch showing five supernumerary teeth (White arrows).

inclined and closely approximated the lingual cortical plate [Table/Fig-3b]; the tooth in the 35-36 region additionally approximated the mesial root of tooth 36 [Table/Fig-3c]. In the right mandibular premolar-molar region, three supernumerary teeth were identified between teeth 44, 45, and 46, closely approximated to one another and to the roots of these teeth [Table/Fig-3a]. The tooth associated with 45 was obliquely inclined, its crown contacting the middle third of the root of the adjacent supernumerary tooth [Table/Fig-3d] and its root contacting the root of tooth 45 [Table/Fig-3e]; the remaining two teeth were vertically inclined. No dilaceration, ankylosis, hypercementosis, or external root resorption was noted in any of the five mandibular supernumerary teeth.

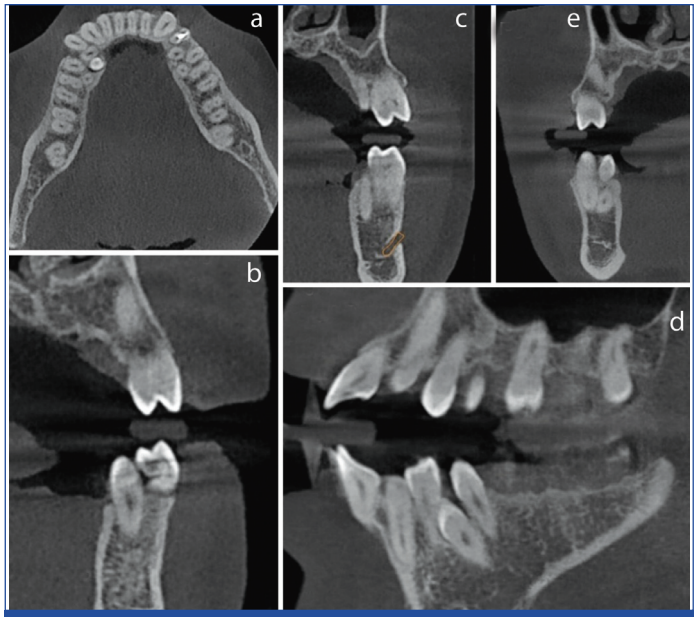

[Table/Fig-3]: CBCT Mandible images (voxel size-0.075 mm)- a) Axial section) showing supernumerary on lingual aspect bilaterally in premolar -molar region; b,c) Sagittal section showing left-side; d,e) Sagittal section showing right-side.

In the maxilla, two supernumerary teeth were identified. A conical, impacted supernumerary tooth was located in the anterior palate, palatal to teeth 11 and 12 [Table/Fig-4a], contacting the middle third of the root of tooth 11 [Table/Fig-4b] and extending into the nasopalatine canal [Table/Fig-4c], with no follicular enlargement, ankylosis, or root resorption. The second supernumerary tooth was located in the left posterior maxilla between teeth 24 and 25, in close contact with the palatal aspect of the root of 24 [Table/Fig-4d] and the crown of 25 [Table/Fig-4e], and exhibited anterior dilaceration without external resorption.

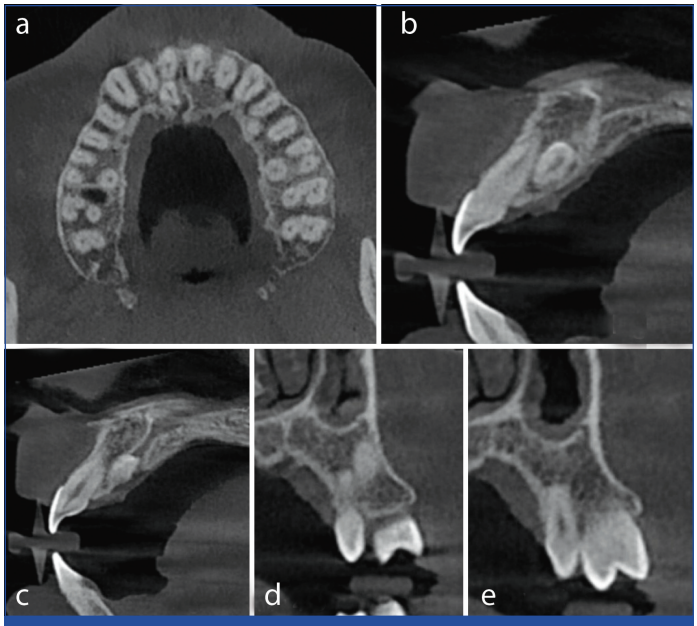

[Table/Fig-4]: CBCT Maxilla images (voxel size-0.075 mm)- a) Axial section at the level of the nasopalatine canal showing supernumerary teeth on palatal aspect of 11 and 24-25; b,c) Sagittal section showing supernumerary tooth in relation 11 palatal aspect; d,e) Coronal section showing supernumerary tooth in relation to 24-25.

A diagnosis of non-syndromic multiple supernumerary teeth was established. Pericoronitis associated with the partially erupted mandibular third molar was considered as a differential diagnosis for the presenting pain; CBCT, however, confirmed the absence of any pathology associated with the supernumerary/impacted teeth and correlated the pain with pulpal involvement of tooth 34, which was managed accordingly. Following endodontic management of tooth 34, the presenting pain resolved completely, and the partially erupted third molar required no further intervention at that visit. Written informed consent was obtained from the patient for all clinical and radiographic procedures, including CBCT imaging, extraction, and endodontic treatment.

At the first visit, the patient was prescribed antibiotics and analgesics for symptomatic relief, pending CBCT evaluation. Root canal treatment of tooth 34 was initiated at the second visit, once CBCT confirmed pulpal involvement; the patient's pain resolved following the procedure. At the third visit, root canal treatment was completed [Table/Fig-5], and the patient was motivated toward extraction of the supernumerary teeth; the patient was initially hesitant but, after counselling, consented to extraction of the left-sided supernumerary teeth alone.

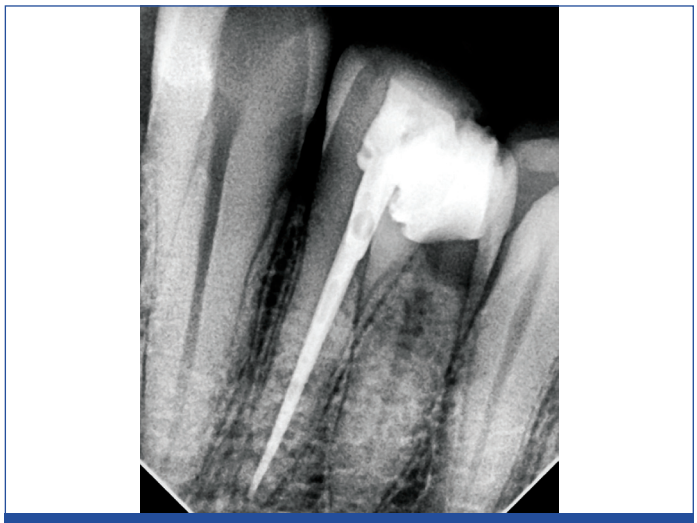

[Table/Fig-5]: Postop RVG showing root treated 34.

Permanent restoration of the access cavity in tooth 34 was carried out one week after completion of root canal treatment. Extraction of the supernumerary teeth in the left mandibular region was performed under inferior alveolar nerve block; a lingual mucoperiosteal flap was elevated, and the teeth were removed using an elevator with slow, controlled luxation [Table/Fig-6a]. One month later, crown preparation and cementation for tooth 34 was carried out [Table/Fig-6b], extraction of the supernumerary teeth having been essential beforehand to permit adequate access and adaptation.

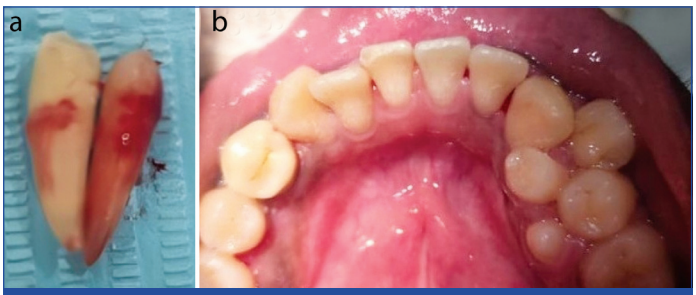

[Table/Fig-6]: a) Extracted supernumerary teeth in relation to 34-35 region; b) After one month of post-extraction and crown replaced in 34.

The patient was counselled regarding the remaining supernumerary teeth in the right mandibular region, and the rationale for their eventual removal was explained, including prevention of cyst formation, root resorption of adjacent teeth, and continued hygiene difficulty. As the maxillary supernumerary teeth were not associated with any functional or hygiene-related complications, a conservative approach with periodic clinical and radiographic monitoring was adopted for both maxillary supernumerary teeth as an alternative to immediate removal.

At the one-month review, adequate healing and gingival repositioning of the extraction site were confirmed. The patient was advised regarding staged extraction of the remaining right-sided mandibular supernumerary teeth and scheduled for periodic follow-up, with continued clinical and radiographic monitoring of impacted maxillary supernumerary teeth.

DISCUSSION

Hyperdontia denotes a numerical excess over the normal dental complement and may present at virtually any point along the maxillary or mandibular arch [1]. Population-based estimates place its frequency somewhere between 0.1% and 3.8%, with the permanent dentition affected more often than the primary dentition and a recognised bias toward male patients [2]. Morphologically, these extra teeth are generally grouped as supplemental, conical, tuberculate, or odontome-like forms, and topographically as mesiodens, paramolar, or distomolar variants [3]. A substantial share of documented hyperdontia is linked to recognisable syndromes, among them Gardner's syndrome, cleidocranial dysplasia, cleft lip and palate, and Ehlers-Danlos syndrome [4]. The picture in the present patient departs from this pattern: several supernumerary teeth were identified without any accompanying systemic or syndromic feature, a combination reported in under 1% of cases in the literature [5].

Of the intraoral sites where such teeth are found, the mandibular premolar region is cited most often as the characteristic location for non-syndromic multiplicity, a pattern this patient's bilateral premolar involvement reproduces closely [6]. No single mechanism fully accounts for this anomaly. Several theories have been put forward, including division of the developing tooth germ, localised dental lamina hyperactivity, atavism, and an autosomal dominant inheritance pattern with variable penetrance [7].

Reported cases of this condition, though limited in number, show considerable variation in presentation. A 15-year-old girl described by Agrawal JM et al., carried four such teeth, two erupted buccally in the maxilla and two impacted; her clinicians extracted the erupted pair while keeping the impacted ones under radiographic review [8]. Tanwar R et al., profiled five similarly non-syndromic patients, the most striking of whom had nine supernumerary teeth spread across both erupted and impacted sites [9]. A larger series still was reported by Krishnan B et al., where 11 extra teeth occupied all four quadrants of a 23-year-old woman's dentition [10]. Pereira MN et al., encountered an even greater burden- 31 supernumerary teeth in an 11-year-old girl - and, notably, chromosomal testing in that case uncovered a pericentric inversion of chromosome 9, a finding that argues for genetic work-up even when no syndrome is clinically evident [11]. Hariri EM et al., subsequently documented an even more extreme count of 41 supernumerary and impacted teeth in a 12-year-old girl whose primary dentition also showed generalised ankylosis [12]. Most recently, in 2026, El HazzatW et al., described five impacted supernumerary teeth alongside an impacted tooth 44 in a 21-year-old male being treated for Class III malocclusion, all removed surgically before orthodontic correction began [13].A summary of these reported cases, alongside the present one, is presented in [Table/Fig-7] [5,8-10,12-15].

Author(s), Year	Place	Age/Sex	No. of Supernumerary Teeth	Location
Inchingolo F et al., 2010 [15] (Index case)	Italy	30 years / M	1	Mandible: 1 distomolar (tooth 49); also had 5 impacted third molars (18, 28, 38, 47, 48) - not supernumerary
Inchingolo F et al, 2010[15] (elder sister)	Italy	17 years / F	5	Maxilla and mandible: paramolars/distomolars (19, 29, 2-10, 39, 49); also had 4 impacted third molars (18, 28, 38, 48) - not supernumerary
Inchingolo F et al., 2010 [15] (younger sister)	Italy	13 years / F	2	Maxilla and mandible: paramolars (19, 29); also had 2 impacted third molars (18, 28) - not supernumerary
Krishnan B et al., 2012 [10]	Chennai Tamil Nadu India	23 years / F	11	Maxilla and mandible, all four quadrants: 2 (right maxilla), 3 (left maxilla), 3 (left mandible, including one impacted mesial to 36), 3 (right mandible, including one impacted mesial to 46)
Agrawal JM et al., 2013 [8]	Sangli, Maharashtra, India	15 years /F	4	Maxilla: 2 erupted (buccal) + 1 impacted (distal to 18); Mandible: 1 impacted (between 35-36)
Tanwar R et al., 2017 [9]	India	5 patients (case series) 25-35 years/4 M and 1 F	Up to 9 (in the most affected patient)	Maxilla and mandible: premolar region. 3 patients had multiple (up to 9) bilaterally impacted/erupted supernumerary teeth; 2 patients had fewer supernumerary premolars
Sawai MA et al., 2019 [5] (index case)	New Delhi, India	30 years /M	10	Mandible: 4 (premolar region, 2 each side); Maxilla: 6 (2 erupted premolar region + 4 impacted, canine-associated)
Sawai MA et al., 2019 [5] (sibling 1)	New Delhi, India	-Age not mentioned/F	3	Mandible: premolar region
Sawai MA et al., 2019[5] (sibling 2)	New Delhi, India	-Age not mentioned/M	1	Maxilla: premolar region

Tbeishat M et al., 2024 [14]	Jordan	8 years/F	4	Maxilla: 2 supplemental primary lateral incisors + 2 impacted permanent supernumeraries, bilateral lateral incisor region
Hariri EM et al., 2025 [12]	Morocco	12 years/F	41 (combined)	Maxilla and mandible, all four quadrants: 41 supernumerary and impacted permanent teeth combined (exact individual split not specified in source); 24 teeth had erupted (20 deciduous + 4 permanent first molars)
El Hazzat W et al., 2026 [13]	Morocco	21 year/M	5	Maxilla: 2 (canine region); Mandible: 3 (paramolar region). An additional impacted permanent tooth 44 was also noted (not counted among the 5 supernumerary teeth)
Present case, 2026	Tiruchirappalli, Tamil Nadu, India	32 years/M	7	Mandible: 5 (bilateral premolar-molar); Maxilla: 2 (anterior and premolar palate)

[Table/Fig-7]: Reported cases of non-syndromic multiple supernumerary teeth in the literature.

In relation to the existing body of literature, the seven supernumerary teeth identified in the present patient- distributed bilaterally across the mandible and maxilla- fall well within the reported range and further support the mandibular premolar region's standing as the site most frequently involved in non-syndromic hyperdontia. Notably, the two arches behaved differently in clinical terms: the mandibular supernumerary teeth, positioned lingually, compromised oral hygiene and contributed to the caries observed at tooth 34, whereas the maxillary supernumerary teeth, positioned palatally, caused no comparable difficulty. This difference may be attributed to the palate's broader, saliva-irrigated surface, which favours self-cleansing, in contrast to the narrow lingual mandibular sulcus, which is more prone to plaque retention. This suggests that the clinical risk posed by a supernumerary tooth depends on its location as much as its number, supporting a selective approach for extraction where hygiene or restorative access is compromised, and observation where teeth remain asymptomatic and well tolerated, consistent with the surveillance strategy adopted by Agrawal JM et al., for impacted, symptom-free supernumerary teeth [8].

The CBCT was central to the management of this case, providing three-dimensional detail on the orientation, depth, and proximity of the supernumerary teeth to adjacent roots and structures such as the nasopalatine canal that would not have been evident on conventional radiography [14]. It also enabled confident exclusion of associated pathology, which directly guided the sequence of extraction and restorative treatment.

CONCLUSION(S)

This case reinforces the value of thorough clinical and radiographic evaluation in diagnosing multiple non-syndromic supernumerary teeth. Extraction is warranted where hygiene, caries control, or restorative treatment is compromised, while a conservative, monitored approach is reasonable for well-tolerated, asymptomatic teeth. CBCT is invaluable in accurately localising supernumerary teeth and guiding individualised treatment planning.

REFERENCES

[1] Scheiner MA, Sampson WJ. Supernumerary teeth: A review of the literature and four case reports. Aust Dent J. 1997;42:160-65.
[2] Rajab LD, Hamdan MA. Supernumerary teeth: Review of the literature and a survey of 152 cases. Int J Paediatr Dent. 2002;12:244-54.
[3] Garvey MT, Barry HJ, Blake M. Supernumerary teeth—an overview of classification, diagnosis and management. J Can Dent Assoc. 1999;65:612-16.
[4] Yagüe-García J, Berini-Aytés L, Gay-Escoda C. Multiple supernumerary teeth not associated with complex syndromes: A retrospective study. Med Oral Patol Oral Cir Bucal. 2009;14:E331-E336.
[5] Sawai MA, Faisal M, Mansoob S. Multiple supernumerary teeth in a nonsyndromic association: Rare presentation in three siblings. J Oral Maxillofac Pathol. 2019;23:163-64.
[6] Yusof WZ. Non-syndrome multiple supernumerary teeth: Literature review. J Can Dent Assoc. 1990;56:147-49.
[7] Hyun HK, Lee SJ, Ahn BD, Lee ZH, Heo MS, Seo BM, et al. Nonsyndromic multiple mandibular supernumerary premolars. J Oral Maxillofac Surg. 2008;66:1366-69.
[8] Agrawal JM, Agrawal MS, Nanjannawar LG, Adaki RV. Non-syndromic multiple supernumerary teeth: A rare entity. BMJ Case Rep. 2013;2013:bcr2012007796.
[9] Tanwar R, Jaitly V, Sharma A, Heralgi R, Ghangas M, Bhagat A. Non-syndromic multiple supernumerary premolars: Clinicoradiographic report of five cases. J Dent Res Dent Clin Dent Prospects. 2017;11(1):48-52.
[10] Krishnan B, Narasimhan B, Nirupama C. Nonsyndromic multiple supernumerary teeth: A case report of 11 supernumerary teeth. J Indian Acad Oral Med Radiol. 2012;24:296-99.
[11] Pereira MN, de Almeida LE, Martins MT, Campos MJS, Fraga MR, Vitral RWF. Multiple hyperdontia: Report of an unusual case. Am J Orthod Dentofacial Orthop. 2011;140:580-84.
[12] Hariri EM, Sellouti M, Ramdi H. Rare nonsyndromic multiple supernumerary and permanent impacted teeth in a young female patient: A case report. Radiol Case Rep. 2025;20:1342-44.
[13] El Hazzat W, Bouyahyaoui N, Zaoui F. Multiple impacted supernumerary teeth in a non-syndromic Class III malocclusion patient: A case report. Cureus. 2026;18(2):e102941.
[14] Tbeishat M, Odeibat AM, Ersheidat A, Mahasneh A. Non-syndromic bilateral supernumerary teeth in the primary and secondary dentition: A rare case report. Cureus. 2024;16(3):e55385.
[15] Inchingolo F, Tatullo M, Abenavoli FM, Marrelli M, Inchingolo AD, Gentile M, et al. Non-syndromic multiple supernumerary teeth in a family unit with a normal karyotype: Case report. Int J Med Sci. 2010;7:378-84.

PARTICULARS OF CONTRIBUTORS:
1. Associate Professor, Department of Oral Pathology and Microbiology, Dhanalakshmi Srinivasan Dental College, Perambalur, Tamil Nadu, India.
2. Associate Professor, Department of Oral Medicine and Radiology, Dhanalakshmi Srinivasan Dental College, Perambalur, Tamil Nadu, India.
3. Associate Professor, Department of Dentistry, Trichy SRM Medical College and Research Centre, Tiruchirappalli, Tamil Nadu, India.
4. Private Practitioner, Tiruchirappalli, Tamil Nadu, India.
5. Professor, Department of Prosthodontics, Tiruchirappalli, Tamil Nadu, India.

NAME, ADDRESS, E-MAIL ID OF THE CORRESPONDING AUTHOR:
Sivagami Muthukrishnan,
Associate Professor, Department of Oral Pathology, Dhanalakshmi Srinivasan Dental College, Perambalur-621113, Tamil Nadu, India.
E-mail: sivagami.ramkumar@gmail.com

PLAGIARISM CHECKING METHODS: [Jain H et al.]
- Plagiarism X-checker: Aug 25, 2026
- Manual Googling: Sep 24, 2026
- iThenticate Software: Sep 26, 2026 (7%)

ETYMOLOGY: Author Origin

EMENDATIONS: 6

AUTHOR DECLARATION:
- Financial or Other Competing Interests: None
- Was informed consent obtained from the subjects involved in the study? Yes
- For any images presented appropriate consent has been obtained from the subjects. Yes

Date of Submission: **Aug 13, 2026**
Date of Peer Review: **Sep 10, 2026**
Date of Acceptance: **Sep 29, 2026**
Date of Publishing: **Dec 01, 2026**